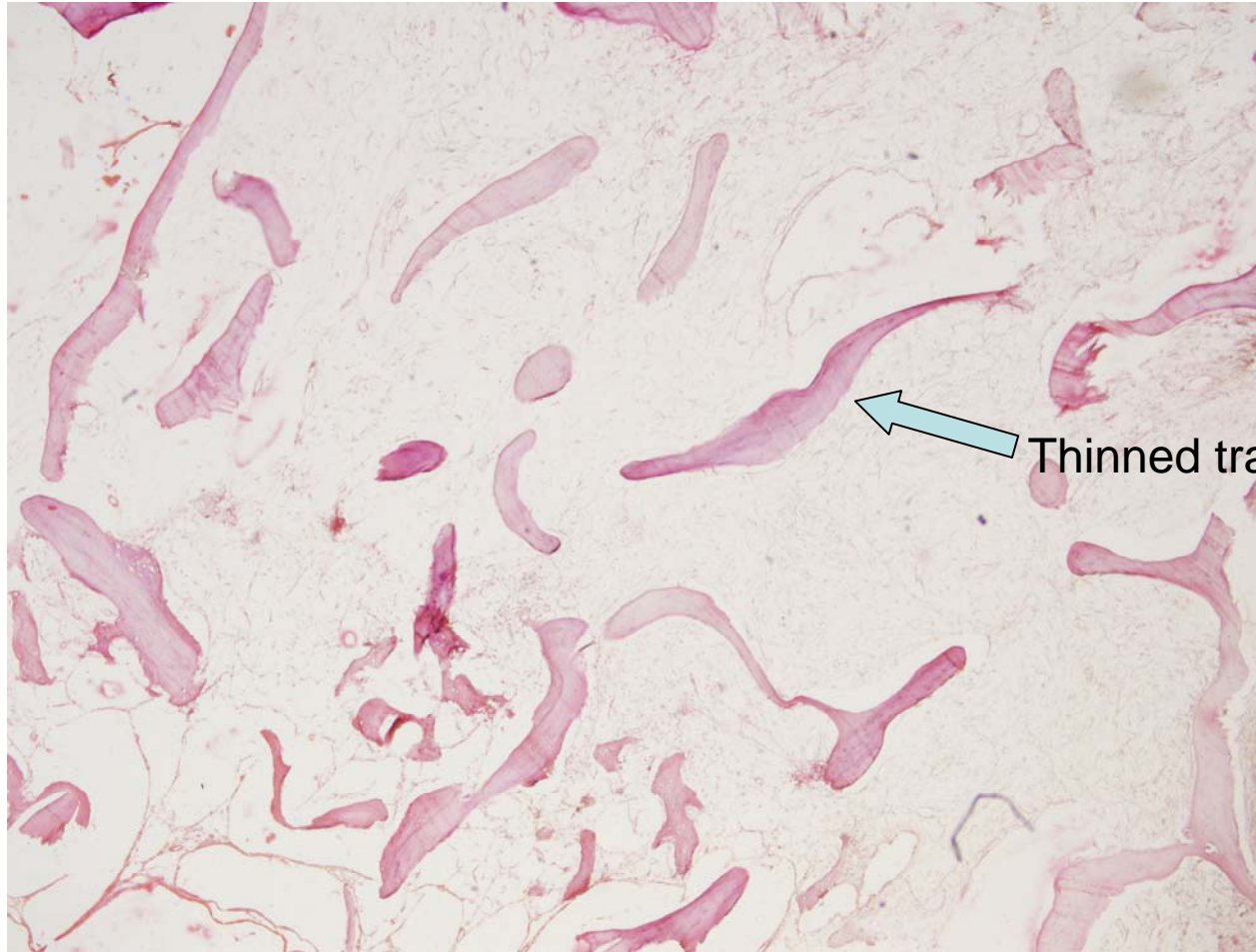

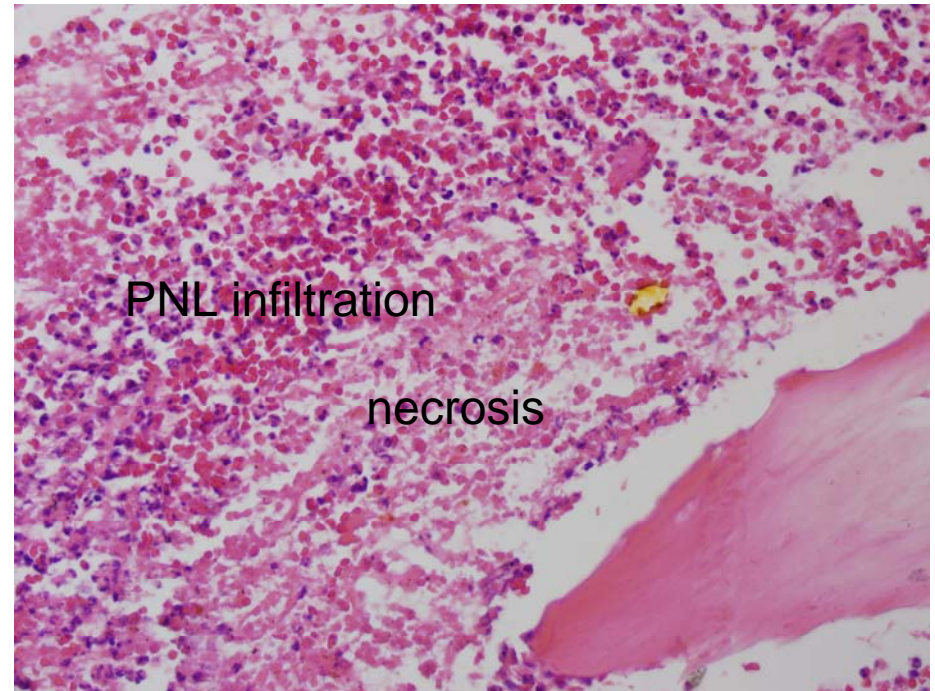
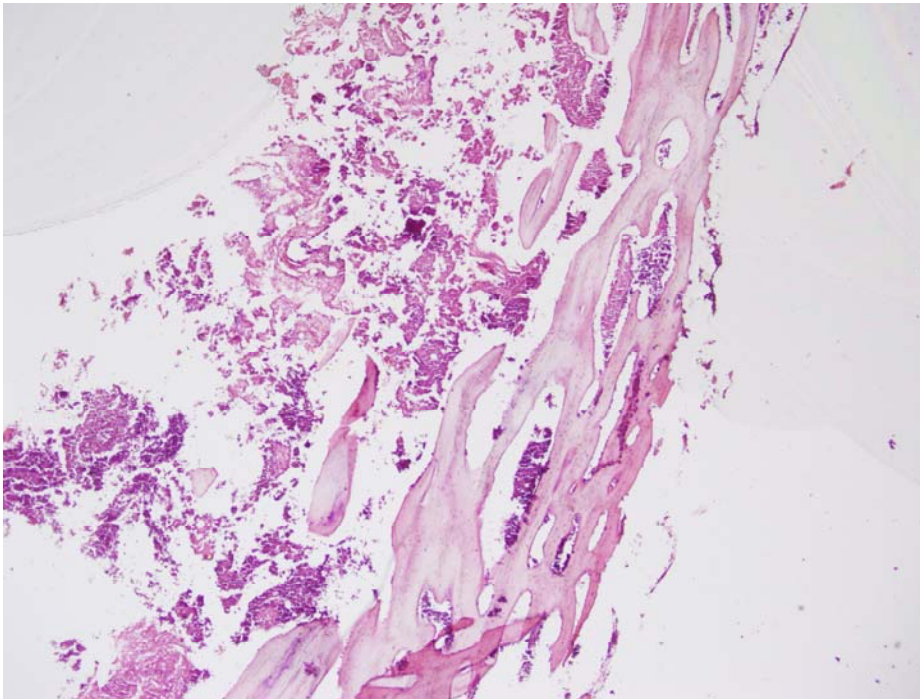
MUSCULOKELETAL SYSTEM
PATHOLOGY LAB

V-23 OSTEOPOROSIS

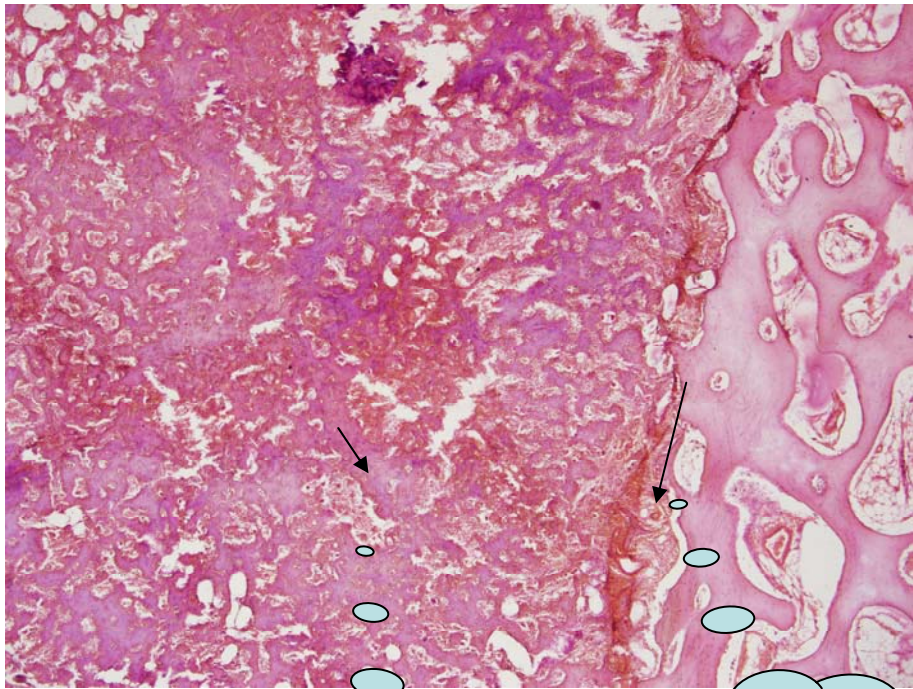


Thinned trabecula

V-12 OSTEOMYELITIS

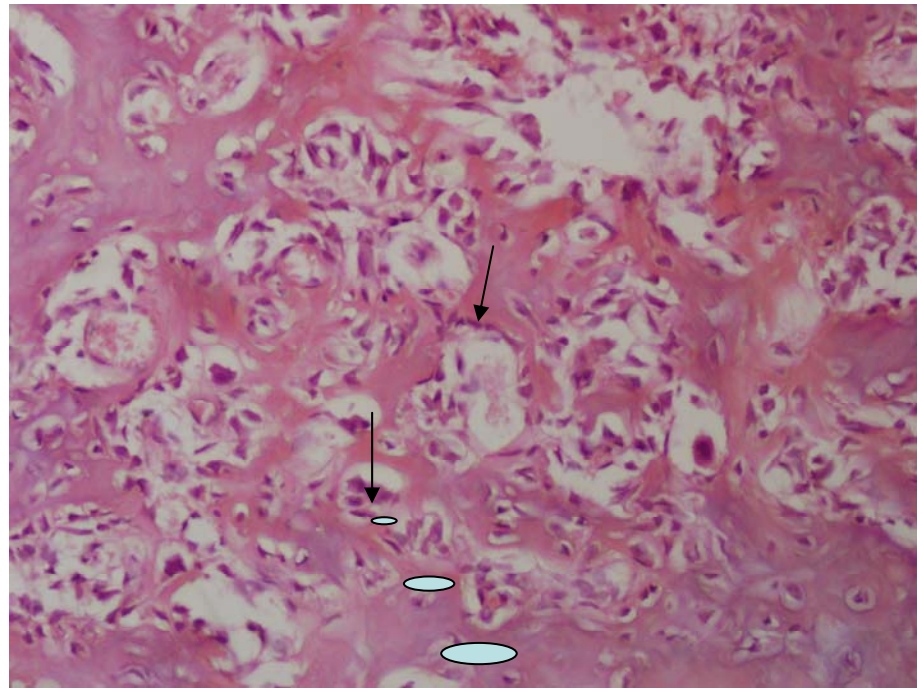


V-15 OSTEOID OSTEOMA



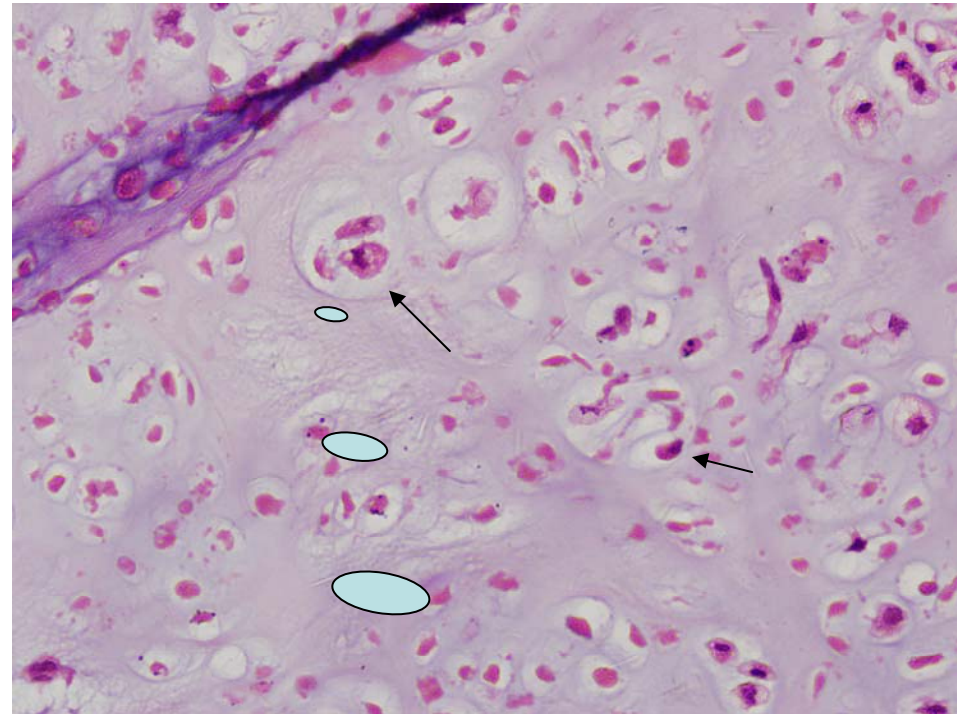
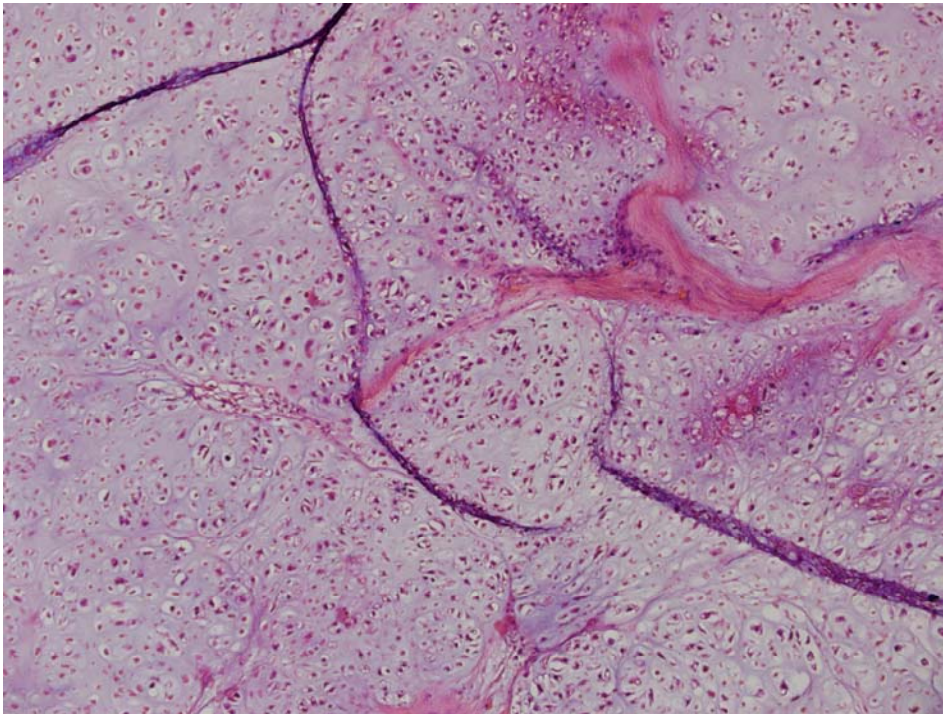
Woven
bone

Tumor
margin



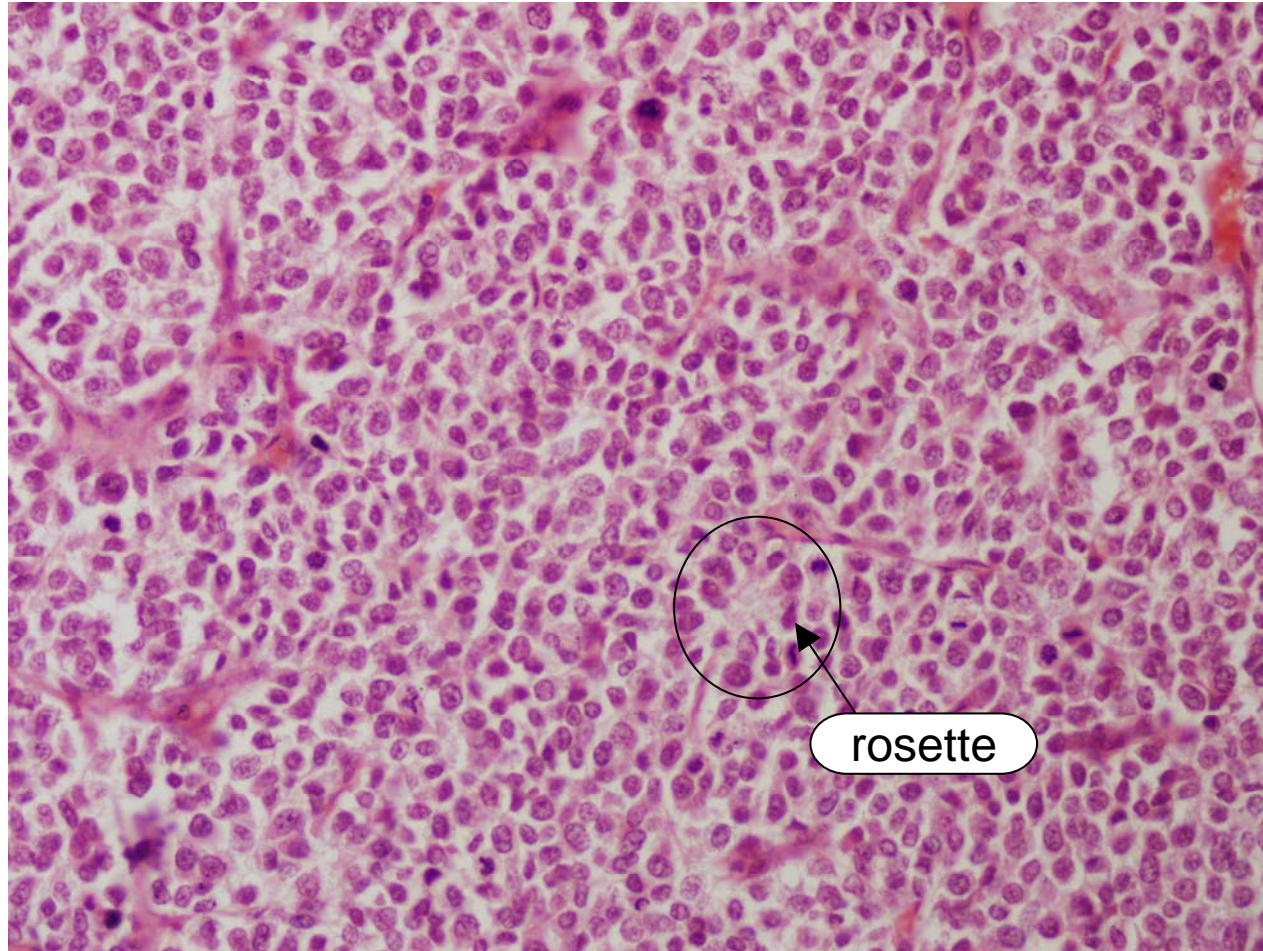
osteoblasts

V-17 CHONDROSARCOMA



Atypical
chondrocytes.
More than one cell in
a lacuna

V-18 EWING SARCOMA



V-19 GIANT CELL TUMOR

